



Case Report

J. Exp. Clin. Med., 2017; 34(2): 145-147
doi: 10.5835/jecm.omu.34.02.012



What to do when facing with atrial thrombus: Surgical treatment of five cases

Serkan Burc Deser*, Mustafa Kemal Demirag

Department of Cardiovascular Surgery, Faculty of Medicine, Ondokuz Mayıs University, Samsun

ARTICLE INFO

ABSTRACT

Article History

Received 14 / 04 / 2015

Accepted 06 / 08 / 2015

Although atrial thrombuses are not very common, may represent as tumors. Urgent surgery is indicated in patients to prevent pulmonary embolism, acute valve obstruction or heart failure. We review here the clinical features, epidemiology, diagnosis and treatment of five interesting cases with atrial thrombuses.

* Correspondence to:

Serkan Burc Deser
Department of Cardiovascular Surgery,
Faculty of Medicine,
Ondokuz Mayıs University,
Samsun, Turkey
e-mail: sbd983@yahoo.com

Keywords:

Atrium
Thrombus
Mass
Surgical treatment

© 2017 OMU

1. Introduction

Atrial thrombus was first described via an autopsy in 1814 and also atrial thrombosis associated with permanent pacemaker leads was first described a few years after the first endocardiac pacemakers were implanted (Prozan et al., 1968). Masses that totally fill the atrium cause life threatening conditions if left untreated. Systemic thrombolysis may be suitable therapy for the right atrium. However, it is ineffective and unsafe for left atrium due to possible risk for embolus (Oginosawa et al., 2002).

2. Case 1

A 47-year-old woman was admitted because of progressive orthopnea and dyspnea with atrial fibrillation. Transthoracic echocardiogram examination

revealed a large right atrial mass (thrombus/myxoma) that was connected to lateral wall of atrium and severe tricuspid valve insufficiency. Thrombus and tricuspid valve were completely excised (Fig. 1) and replaced with 33 no bovine bioprostheses valve (St Jude, Bioprostheses, Minn. USA). The patient was discharged two weeks later with oral warfarin administration.

Case 2

A 65-year-old woman patient presented with progressive shortness of breath, swelling in her legs. The patient had a pacemaker implantation history due to atrio-ventricular complete block, which had been placed 12 years ago. Echocardiography revealed a thrombus attached to the pacing lead in the right atrium, grade 3 tricuspid regurgitation. We excised the tricuspid valve

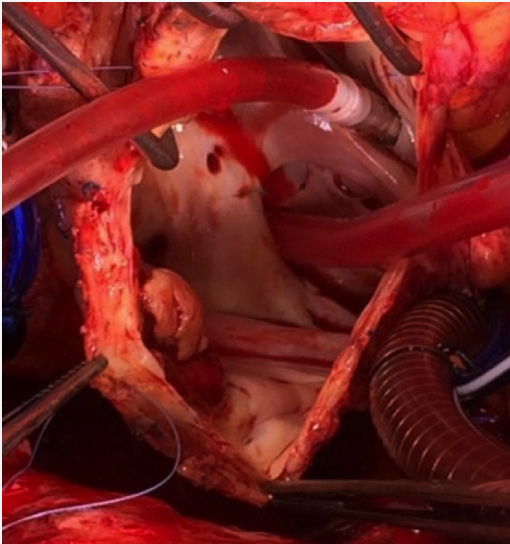


Fig. 1. Internal view of thrombus on the lateral wall of the right atrium

and replaced with with 33 no bovine bioprostheses valve (St Jude, Bioprostheses, Minn. USA) and excised the internal leads of the previous pacemaker with thrombus and placed with permanent external pacemaker leads. Over the following days, the patient developed a respiratory infection with progressive clinical deterioration that led to sepsis, and despite intensive antibiotic therapy, she progressively deteriorated and finally died.

Case 3

A 63-year old woman patient with long-standing history of Alzheimer's demans, diabetes mellitus, hypertension, cerebrovascular disease and atrial fibrillation was referred to our hospital because of worsening acute ischemia (cold, pale and cyanotic) of the right lower extremity and pain. Echocardiography revealed a 25x11 mm echo-low-dense structure within the left atrium and non valvular atrial fibrillation. Emergency surgery was performed with local anaesthesia for acute femoral embolus. The patient underwent elective cardiac surgery. Thrombus in the left atrium was excised. Over the following days her right leg worsened and was amputated above the knee level. Two weeks after the open heart surgery the patient developed a respiratory infection with progressive clinical deterioration and died.

Case 4

A 52-year-old woman patient presented with progressive shortness of breath. In view of the history of rheumatic fever, mitral valve replacement was performed with mechanical valve in 2003. A severely dilated left atrium

containing a large (1.5 cm-2.4 cm) and highly mobile mass relevant with the mechanical valve was revealed. Mitral valve and thrombus was excised and replaced with 31 no mechanical valve (St Jude, Mechanical, Minn. USA). The postoperative course was uneventful and she was discharged 10 days later with oral warfarin therapy.

Case 5

A 67-year-old woman presented with progressive shortness of breath, swelling in the legs. She had a prior history hypertension and mitral valve replacement with mechanical valve in 2007. A transthoracic echocardiogram was performed. 2.3 cm² cm and highly mobile mass relevant with the mechanical valve was revealed. Mitral valve and thrombus (Fig. 2) was excised and replaced with 29 no bovine bioprostheses valve (St Jude, Bioprostheses, Minn. USA). The patient was discharged home 7 days later with oral warfarin therapy.

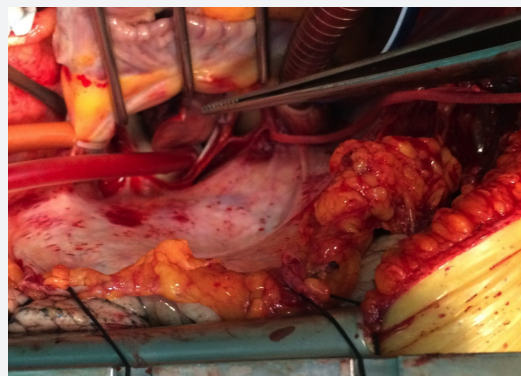

Fig. 2. Thrombus on the mitral valve

3. Discussion

The etiology of thrombus comprises structural cardiac disease, atrial fibrillation and metastatic carcinoma. Atrial fibrillation is associated with thromboembolism including stroke or pulmonary embolism. Left atrial thrombus is often associated with mitral valve stenosis, atrial fibrillation and hypertrophic cardiomyopathy. Association of atrial fibrillation with stroke is 5% to 12% per year. Advanced age, diabetes mellitus, heart failure, history of previous myocardial infarction and embolism increase the risk of stroke in patients with atrial fibrillation (Barakat et al., 2000). The presence of atrial thrombi can cause inflow and outflow obstruction (Hartier et al., 1999), and may present with tiredness, feet swelling, hepatomegaly, ascites, facial and arm swelling or pain, discoloration, visible collateral circulation and superior vena cava syndrome (Barakat et al., 2000). The diagnosis is made by transthoracic echocardiography or transesophageal echocardiography, computed

tomography scan as well as magnetic resonance imaging (MRI) (Mularek-Kubzdela et al., 1997). Receiving suboptimal anticoagulant therapy leads to thromboses. Thrombotic occlusion of mechanical valves (3 per 100 patients-years) is seen more often rather than with a bioprosthesis valves (1.9 per 100 patients-years) (Rose et al., 2002).

All patients we had operated except one (complete AV block) had atrial fibrillation. Four patients had a history of inappropriate administration of warfarin therapy. Warfarin is the first treatment option for

valvular/non-valvular atrial fibrillation or after valve replacement to prevent peripheral embolism and thrombus formation in the atriums/valves. However, the response to the thrombolytic therapy is poor and mostly ineffective and unsafe, it is often recommended as a bridge to surgery (Rose et al., 2002). In conclusion, diagnosis of atrial thrombus is essential and attention must be paid to choose the appropriate treatment strategy, our recommendation is prompt surgical removal of the thrombus should be the first option.

REFERENCES

- Barakat, K., Robinson, M.N., Spurrell, R.A., 2000. Transvenous pacing lead-induced thrombosis: A series of cases with review of the literature. *Cardiology*. 93, 142-148. doi: 7018.
- Chartier, L., Béra, J., Delomez, M., Asseman, P., Beregi, J.P., Bauchart, J.J., Warembourg, H., Théry, C., 1999. Free-floating thrombi in right heart: Diagnosis, management, and prognostic indexes in 38 consecutive patients. *Circulation*. 99, 2779-2783. doi: <https://doi.org/10.1161/01.CIR.99.21.2779>.
- Mularek-Kubzdela, T., Grygier, M., Grajek, M., Cieslinski, A., 1997. Right atrial thrombosis: a difficult diagnostic and therapeutic problem. *Przegląd Lekarski*. 54, 515-519.
- Oginosawa, Y., Abe, H., Nakashima, Y., 2002. The incidence and risk factors for venous obstruction after implantation of transvenous pacing leads. *Pacing. Clin. Electrophysiol.* 25, 1605-1616. doi: 10.1046/j.1460-9592.2002.01605.x.
- Prozan, G.B. et al., 1968. Pulmonary thromboembolism in the presence of an endocardiac pacing catheter. *JAMA*. 206, 1564-1565. doi:10.1001/jama.1968.03150070102024.
- Rose, P.S., Punjabi, N.M., Pearse, D.B., 2002. Treatment of right heart thromboemboli. *Chest*. 121, 806-814. doi: <http://dx.doi.org/10.1378/chest.121.3.806>.